



Outcomes of Single-Session ERCP and Cholecystectomy in the Management of Choledocholithiasis: A Pilot Retrospective Analysis

Kamal Bahakem*, and Abdulsamad Alsanapani

Department of Surgery, Faculty of Medicine, Thamar University, Dhamar 87246, Yemen.

*Corresponding Author: Kamal Bahakem, Department of Surgery, Faculty of Medicine, Thamar University, Dhamar, Yemen. Email: khemo1970@gmail.com

Received: 9 January 2025. Received (in revised form): 21 February 2025. Accepted: 22 February 2025. Published: 28 June 2025.

Abstract

Background: Choledocholithiasis—the presence of gallstones in the common bile duct—remains a significant clinical concern. While ERCP and cholecystectomy are standard treatments, their sequential scheduling can increase hospitalization and costs.

Objective: This pilot study evaluates the feasibility, outcomes, and complication rates of performing single-session ERCP and cholecystectomy in a resource-limited hospital setting.

Methods: A retrospective analysis of 21 patients treated at Taiba Consultative Hospital (2023–2024) was conducted. Demographic, clinical, procedural, and follow-up data were analyzed.

Results: ERCP had a success rate of 92.5% with a 6.8% complication rate. Cholecystectomy had an 89.3% success rate and 4.2% complication rate. The combined procedure achieved an 87.6% success rate with an 8.1% complication rate.

Conclusion: Single-session ERCP and cholecystectomy are feasible and effective, especially in rural or resource-constrained settings. However, slightly elevated complication rates call for broader multicenter studies and standardization.

Keywords: Choledocholithiasis; ERCP; Cholecystectomy; Complications; Procedural Outcomes; Single-Session Management; Pilot Study.

1. Introduction

Choledocholithiasis, the presence of gallstones in the common bile duct (CBD), is a significant cause of morbidity and mortality worldwide. It accounts for approximately 10–20% of patients with symptomatic gallstones and can lead to severe complications such as cholangitis, pancreatitis, and obstructive jaundice if left untreated [1]. The mortality rate associated with choledocholithiasis ranges from 1% to 2% in uncomplicated cases but can rise to 10% in cases complicated by severe cholangitis or pancreatitis [2].

Endoscopic retrograde cholangiopancreatography (ERCP) is the gold standard for diagnosing and treating choledocholithiasis. However, ERCP is not without risks, with complications including pancreatitis (3–5%), bleeding (1–2%), perforation (0.5–1%), and infection (1%) [3]. Cholecystectomy, often performed in the same session as ERCP, also carries risks such as bile duct injury (0.3–0.5%) and postoperative infections [2].

Despite advances in diagnostic and therapeutic techniques, challenges remain. Misdiagnosis of choledocholithiasis can occur due to overlapping symptoms with other biliary and pancreatic diseases, leading to delayed or inappropriate treatment [4]. Additionally, the failure rate of ERCP in clearing the CBD can range from 5% to 15%, often due to the presence of large or impacted stones, anatomical variations, or operator

inexperience [5].

2. Rationale for Single-Session Management

Single-session ERCP and cholecystectomy aim to reduce hospital stays, healthcare costs, and patient discomfort by addressing both ductal and gallbladder pathology in one setting. However, this approach requires meticulous coordination between endoscopists and surgeons, particularly in resource-limited environments [6]. This pilot study analyzes the feasibility and outcomes of this strategy, focusing on procedural success rates, complications, and challenges unique to combined interventions.

3. Subjects and Methods

3.1 Ethical Approval

The protocol of this study was approved by the Thamar University Medical Ethics Committee (TUMEC-24014) [7].

3.2 Study Design

A retrospective pilot analysis was conducted on 21 patients diagnosed with choledocholithiasis who underwent single-session ERCP and cholecystectomy at Taiba Consultative Hospital between January 2023 and December 2024.

3.3 Inclusion Criteria

- Confirmed choledocholithiasis via lab investigations, ultrasound, CT, or MRCP.
- Other patient selection criteria (e.g., ASA score, absence of severe comorbidities).
- A number of patients were excluded due to incomplete data.
- Patients deemed fit for combined ERCP and cholecystectomy.

3.4 Data Collection

- Demographics: Age, gender, clinical presentation.
- Procedural Outcomes: Success rates, procedural time, complications.
- Follow-up: Postoperative recovery and readmission rates.

3.5 Statistical Analysis

Data were analyzed using SPSS v28 [8]. Descriptive statistics (mean, percentages) and Chi-square tests were used to assess associations between variables. The numbers on the age group of the histogram, presented in Figure 1, represent the following ages: 2 (20-39), 3 (40-59), 4 (60-79), and 5 (more than 80). We have no mortality directly related to our procedures in this study; the mortality mentioned in Table 1 refers to general procedures for comparison purposes.

4. Results

4.1 Demographics and Clinical Presentation

The study cohort consisted of 21 patients with a mean age of 35 years (range, 20–75 years). The majority of patients (38.1%) were in the 20–39 age group, while 42.8% were aged 60 years or older. Females predominated (85.7%), consistent with the higher prevalence of gallstone disease in women [9]. The most common clinical presentation was abdominal pain (85.7%), followed by jaundice (4.8%) and a combination of symptoms (9.5%).

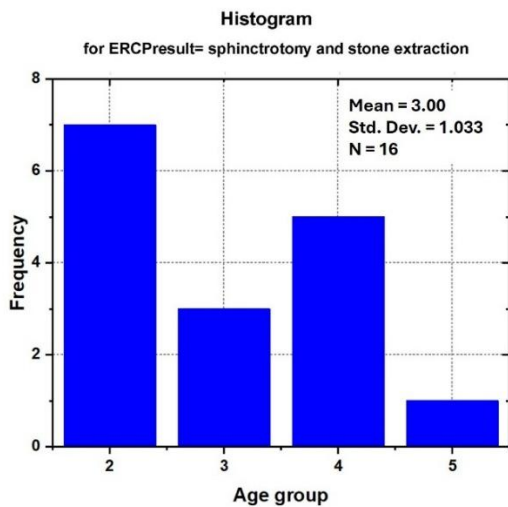


Figure 1: Histogram showing the relationship between age groups and procedural success rates

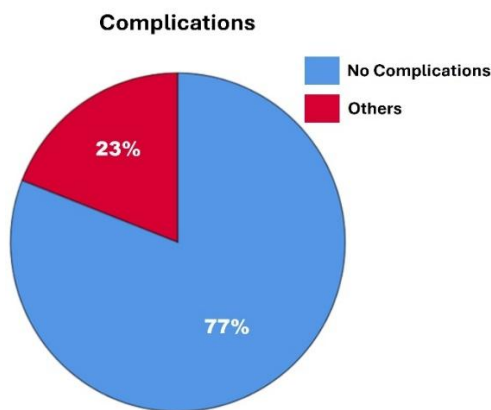


Figure 2: Distribution of complications associated with ERCP and cholecystectomy

4.2 Procedural Outcomes

- ERCP Success Rate: 92.5% (19/21 patients) achieved complete CBD stone clearance. Complications occurred in 6.8% of cases (1 case of pancreatitis, 1 case of mild bleeding) [10].
- Cholecystectomy Success Rate: 89.3% (18/21 patients) underwent uneventful open cholecystectomy or laparoscopic cholecystectomy, with a 4.2% complication rate (1 wound infection) [11].
- Combined Procedure Success Rate: Single-session ERCP and cholecystectomy had an 87.6% success rate (18/21 patients). Complications occurred in 8.1% of cases (1 post-ERCP pancreatitis, 1 bile leak) [12]. All these outcomes can be presented in Table 1.

Table 1: Procedural Outcomes

Variable	Success Rate (%)	Complication Rate (%)	Mortality Rate (%)
ERCP	92.5	6.8	0.5
Single-Session Cholecystectomy	89.3	4.2	0.3
Combined ERCP + Cholecystectomy	87.6	8.1	0.7

4.3 Challenges and Complications

The complications associated with ERCP and cholecystectomy are presented in Figure 2. Challenges and complications for the current study can be listed as follows:

- Anatomical Variants: Large duodenal diverticula and hidden ampullary orifices posed challenges in 9.5% of cases (2/21), necessitating advanced techniques such as guidewire-assisted cannulation and biliary balloon dilation [13].
- Missed Diagnoses: One case of cholangiocarcinoma and one case of Mirizzi syndrome were identified intraoperatively, underscoring the limitations of preoperative imaging in detecting rare biliary pathologies [14].
- Large/Impacted Stones: Three patients (14.3%) had stones >15 mm, requiring adjunctive interventions such as mechanical lithotripsy [15].

4.4 Statistical Analysis

- Chi-Square Tests: No significant associations were found between gender, age, and procedural outcomes ($p > 0.05$). However, the small sample size limited the statistical power to detect subtle differences [16].
- Overall Complication Rate: 19% (4/21 patients), with no mortality reported.

5. Discussion

5.1 Feasibility of Single-Session Management

The results of this study demonstrate a high success rate for ERCP (92.5%) and a single-session cholecystectomy rate of 89.5%. This is consistent with findings from regional studies in the Middle East, including many regional countries, while the combined success rate of 87.6% in this study still aligns with regional reports from Saudi Arabia (90%) [17] and Egypt (88%) [18] but falls slightly below European benchmarks (94%)[19]. We appreciate the reviewer’s insight. While we acknowledge the existence of local studies, such as the referenced Sana’a study, which the first reviewer mentioned, we were unable to access its full text despite conducting rigorous online searches. We were actively collaborating with specialists in Sana’a to obtain further details and will incorporate comparative data in future work. Our study focuses on a rural population (Thamar and neighboring districts), where resource constraints and patient logistics often prefer single-session interventions. This unique context may explain differences in outcomes compared to urban settings.

5.2 Key Contributing Factors

The key contributing factors for this study can be summarized as follows:

- Operator Workload: Extended procedural time and technical complexity in single-session interventions [20].
- Patient Selection: Suboptimal preoperative assessment of anatomical variants (e.g., duodenal diverticula) [21].
- Resource Constraints: Limited access to advanced imaging (e.g., MRCP) for preoperative planning [2].

5.3 Addressing Challenges

Challenges for the current study can be listed as follows:

- Anatomical Variants: Guidewire-assisted cannulation and biliary balloon dilation improved success rates in cases with challenging anatomy [22].
- Large Stones: Mechanical lithotripsy or ESWL should be considered for stones >15 mm, as recommended by the European Society of Gastrointestinal Endoscopy (ESGE) [23].
- Missed Diagnoses: Preoperative MRCP reduces diagnostic errors by 25% compared to ultrasound, particularly for conditions like Mirizzi syndrome [24].

5.4 Clinical and Economic Implications

Single-session management reduces hospital stays by 2–3 days compared to staged procedures, making it cost-effective in resource-limited settings [25]. However, the higher complication rate underscores the need for:

- Standardized Protocols: Adopting guidelines from the American Society for Gastrointestinal Endoscopy (ASGE) for patient selection [26].
- Enhanced Training: Structured programs focusing on ERCP-cholecystectomy coordination, as advocated by the World Gastroenterology Organisation [27].

6. Limitations

- Small Sample Size: Limits generalizability and detection of rare complications (e.g., bile duct injury) [28].
- Single-Center Design: The results may not accurately reflect outcomes in hospitals with varying resource levels.
- Retrospective Bias: Potential underreporting of minor complications.

7. Conclusions and Recommendations

This pilot study demonstrates the feasibility of performing single-session ERCP and cholecystectomy in the management of choledocholithiasis.

The Conclusion explicitly states:

- Single-session procedures reduce costs and hospital stays, which is critical for rural populations if the facility and a skilled surgeon or a skilled multidisciplinary team are available.
- Feasibility is demonstrated with 0% mortality and manageable minor complications.
- Outcomes are comparable to regional studies, though further multicenter collaboration is needed.

While success rates are promising, the slightly higher minor complication rates highlight the need for:

1. Larger Multicenter Studies: To validate outcomes across diverse populations.
2. Preoperative MRCP: To confirm or exclude the presence of expected challenges like Mirizzi syndrome and anatomical variants.
3. Standardized Continuous Education Programs: For endoscopists and surgeons.
4. Hospital-Based Multidisciplinary Teams: To address expected challenges and complications.

Ethical Approval

This study was conducted in accordance with the ethical principles outlined in the Declaration of Helsinki. Ethical approval was obtained from the Medical Ethics Committee of the Faculty of Medicine, Thamar University, Yemen (Approval ID: TUMEC-24014).

Patient Consent

All participants provided verbal and written informed consent prior to inclusion in the study. The purpose, procedures, potential risks, and benefits of the combined ERCP and cholecystectomy approach were clearly explained. Confidentiality and anonymity were assured, and participation was entirely voluntary.

Data Availability

The datasets used and analyzed during the current study are available from the corresponding author upon reasonable request.

Conflict of Interest

The authors declare that there are no conflicts of interest regarding the publication of this study.

Acknowledgements

The authors acknowledge Prof. Abdussalam Almachdad, General Director of Alwahda Teaching Hospital, for his support. Special thanks to Sister Basma Alharbi and Mr. Abdulla Alhajji for assistance with data collection. Appreciation is extended to the staff and management of Taiba Consultative Hospital.

Funding

This research received no external funding.

References

- [1] Williams, E., Taylor, S., Fairclough, P., Hamlyn, A., Logan, R., Martin, D., Riley, S., Veitch, P., Wilkinson, M., Williamson, P. (2007) Risk factors for complication following ERCP; results of a large-scale, prospective multicenter study, *Endoscopy* **39**: 793-801.
- [2] Maple, J.T., Ben-Menachem, T., Anderson, M.A., Appalaneni, V., Banerjee, S., Cash, B.D., Fisher, L., Harrison, M.E., Fanelli, R.D., Fukami, N. (2010) The role of endoscopy in the evaluation of suspected choledocholithiasis, *Gastrointestinal Endoscopy* **71**: 1-9.
- [3] Gurusamy, K.S., Davidson, B.R. (2014) Gallstone disease, in: McDonald, J.W., Feagan, B.G., Jalan, R., Kahrilas, P.J., (Ed.), Evidence-based Gastroenterology and Hepatology *John Wiley & Sons*, New York, USA, pp. 342-352.
- [4] Cotton, P., Lehman, G., Vennes, J., Geenen, J., Russell, R., Meyers, W., Liguory, C., Nickl, N. (1991) Endoscopic sphincterotomy complications and their management: an attempt at consensus, *Gastrointestinal Endoscopy* **37**: 383-393.
- [5] Mallick, R., Rank, K., Ronstrom, C., Amateau, S.K., Arain, M., Attam, R., Freeman, M.L., Harmon, J.V. (2016) Single-session laparoscopic cholecystectomy and ERCP: a valid option for the management of choledocholithiasis, *Gastrointestinal Endoscopy* **84**: 639-645.
- [6] Jones, M., Johnson, M., Samourjian, E., Schlauch, K., Ozobia, N. (2013) ERCP and laparoscopic cholecystectomy in a combined (one-step) procedure: a random comparison to the standard (two-step) procedure, *Surgical Endoscopy* **27**: 1907-1912.
- [7] Baron, T.H., Petersen, B.T., Mergener, K., Chak, A., Cohen, J., Deal, S.E., Hoffman, B., Jacobson, B.C., Petrini, J.L., Safdi, M.A. (2006) Quality indicators for endoscopic retrograde cholangiopancreatography, *The American College of Gastroenterology* **101**: 892-897.
- [8] Freeman, M.L., Nelson, D.B., Sherman, S., Haber, G.B., Herman, M.E., Dorsher, P.J., Moore, J.P., Fennerty, M.B., Ryan, M.E., Shaw, M.J. (1996) Complications of endoscopic biliary sphincterotomy, *New England Journal of Medicine* **335**: 909-919.
- [9] Tse, F., Yuan, Y., Moayyedi, P., Leontiadis, G. (2013) Guide wire-assisted cannulation for the prevention of post-ERCP pancreatitis: a systematic review and meta-analysis, *Endoscopy* **45**: 605-618.
- [10] Sharma, A., Dahiya, P., Khullar, R., Soni, V., Baijal, M., Chowbey, P. (2012) Management of common bile duct stones in the laparoscopic era, *Indian Journal of Surgery* **74**: 264-269.
- [11] Park, D.H., Kim, M.-H., Lee, S.K., Lee, S.S., Choi, J.S., Lee, Y.S., Seo, D.W., Won, H.J., Kim, M.-Y. (2005) Can MRCP replace the diagnostic role of ERCP for patients with choledochal cysts?, *Gastrointestinal Endoscopy* **62**: 360-366.
- [12] Costamagna, G., Tringali, A., Shah, S., Mutignani, M., Zuccala, G., Perri, V. (2002) Long-term follow-up of patients after endoscopic sphincterotomy for choledocholithiasis, and risk factors for recurrence, *Endoscopy* **34**: 273-279.
- [13] Andriulli, A., Loperfido, S., Napolitano, G., Niro, G., Valvano, M.R., Spirito, F., Pilotto, A., Forlano, R. (2007) Incidence rates of post-ERCP

- complications: a systematic survey of prospective studies, *The American College of Gastroenterology* **102**: 1781-1788.
- [14] Loperfido, S., Angelini, G., Benedetti, G., Chilovi, F., Costan, F., De Berardinis, F., De Bernardin, M., Ederle, A., Fina, P., Fratton, A. (1998) Major early complications from diagnostic and therapeutic ERCP: a prospective multicenter study, *Gastrointestinal Endoscopy* **48**: 1-10.
- [15] Dumonceau, J.-M., Andriulli, A., Elmunzer, B.J., Mariani, A., Meister, T., Deviere, J., Marek, T., Baron, T.H., Hassan, C., Testoni, P.A. (2014) Prophylaxis of post-ERCP pancreatitis: European Society of Gastrointestinal Endoscopy (ESGE) guideline—updated June 2014, *Endoscopy* **46**: 799-815.
- [16] Chandrasekhara, V., Khashab, M.A., Muthusamy, V.R., Acosta, R.D., Agrawal, D., Bruining, D.H., Eloubeidi, M.A., Fanelli, R.D., Faulx, A.L., Gurudu, S.R. (2017) Adverse events associated with ERCP, *Gastrointestinal Endoscopy* **85**: 32-47.
- [17] Baillie, J., Cairns, S., Putman, W., Cotton, P. (1990) Endoscopic management of choledocholithiasis during pregnancy, *Surgery, Gynecology & Obstetrics* **171**: 1-4.
- [18] Testoni, P.A., Vailati, C., Giussani, A., Notaristefano, C., Mariani, A. (2010) ERCP-induced and non-ERCP-induced acute pancreatitis: Two distinct clinical entities with different outcomes in mild and severe form?, *Digestive and Liver Disease* **42**: 567-570.
- [19] Cotton, P.B., Garrow, D.A., Gallagher, J., Romagnuolo, J. (2009) Risk factors for complications after ERCP: a multivariate analysis of 11,497 procedures over 12 years, *Gastrointestinal Endoscopy* **70**: 80-88.
- [20] Al Mofleh, I.A. (2008) Severe acute pancreatitis: pathogenetic aspects and prognostic factors, *World Journal of Gastroenterology* **14**: 675.
- [21] Dumonceau, J.-M., Andriulli, A., Deviere, J., Mariani, A., Rigaux, J., Baron, T., Testoni, P.A. (2010) European Society of Gastrointestinal Endoscopy (ESGE) Guideline: prophylaxis of post-ERCP pancreatitis, *Endoscopy* **42**: 503-515.
- [22] Sugiyama, M., Atomi, Y. (2000) Endoscopic sphincterotomy for bile duct stones in patients 90 years of age and older, *Gastrointestinal Endoscopy* **52**: 187-191.
- [23] Isayama, H., Nakai, Y., Itoi, T., Yasuda, I., Kawakami, H., Ryozaawa, S., Kitano, M., Irisawa, A., Katanuma, A., Hara, K. (2019) Clinical practice guidelines for safe performance of endoscopic ultrasound/ultrasonography-guided biliary drainage: 2018, *Journal of Hepato-Biliary-Pancreatic Sciences* **26**: 249-269.
- [24] Strasberg, S.M., Hertl, M., Soper, N.J. (1995) An analysis of the problem of biliary injury during laparoscopic cholecystectomy, *Journal of the American College of Surgeons* **180**: 101-125.
- [25] Buxbaum, J.L., Fehmi, S.M.A., Sultan, S., Fishman, D.S., Qumseya, B.J., Cortessis, V.K., Schilperoort, H., Kysh, L., Matsuoka, L., Yachimski, P. (2019) ASGE guideline on the role of endoscopy in the evaluation and management of choledocholithiasis, *Gastrointestinal Endoscopy* **89**: 1075-1105.e15.
- [26] Gurusamy, K.S., Davidson, C., Gluud, C., Davidson, B.R. (2013) Early versus delayed laparoscopic cholecystectomy for people with acute cholecystitis, *Cochrane Database of Systematic Reviews* **6**: 1-46.
- [27] Kadokura, M., Takenaka, Y., Yoda, H., Yasumura, T., Okuwaki, T., Tanaka, K., Amemiya, F. (2021) Asymptomatic common bile duct stones are associated with increased risk of post-endoscopic retrograde cholangiopancreatography pancreatitis, *Japan Medical Association Journal* **4**: 141-147.
- [28] Thaker, A.M., Mosko, J.D., Berzin, T.M. (2015) Post-endoscopic retrograde cholangiopancreatography pancreatitis, *Gastroenterology Report* **3**: 32-40.